

Erbium laser in gynecology

Z. Vizintin, M. Lukac, M. Kazic & M. Tettamanti

To cite this article: Z. Vizintin, M. Lukac, M. Kazic & M. Tettamanti (2015) Erbium laser in gynecology, *Climacteric*, 18:sup1, 4-8

To link to this article: <http://dx.doi.org/10.3109/13697137.2015.1078668>



Published online: 14 Sep 2015.



Submit your article to this journal [↗](#)



View related articles [↗](#)



View Crossmark data [↗](#)

Erbium laser in gynecology

Z. Vizintin, M. Lukac, M. Kazic and M. Tettamanti*

Fotona, Ljubljana, Slovenia; *Latinmed, Stuart, Florida, USA

Key words: ERBIUM YAG LASER, VAGINAL RELAXATION SYNDROME, STRESS URINARY INCONTINENCE, PELVIC ORGAN PROLAPSE, VAGINAL ATROPHY, COLLAGEN

ABSTRACT

The aim of this paper is to present a novel laser technology utilizing the erbium YAG laser for various minimally invasive, non-surgical procedures in gynecology. Non-ablative, thermal-only SMOOTH-mode erbium pulses are used to produce vaginal collagen hyperthermia, followed by collagen remodeling and the synthesis of new collagen fibers, resulting in improved vaginal tissue tightness and elasticity. This erbium laser technology is used for treatments of vaginal laxity, stress urinary incontinence, pelvic organ prolapse and vaginal atrophy. In the period from 2010 to 2014, several clinical studies covering all four indications were conducted with the aim to prove the efficacy and safety of this novel technology. An overview is presented of the results of these studies where several objective as well as subjective assessment tools were used. The results have shown that SMOOTH-mode erbium laser seems to be an effective and safe method for treating vaginal laxity, stress urinary incontinence, pelvic organ prolapses and vaginal atrophy.

INTRODUCTION

One of the first reports on the use of erbium YAG (Er:YAG) laser technology for gynecological treatments dates back to 2000 when Dr Claudia Pidal and colleagues reported on the use of a Fotona Fidelis Er:YAG laser for treating vaginal tissue¹. The results were impressive. The treatment was effective and painless and led to the rapid development of various erbium ablative procedures, including the treatment of human papilloma virus infections, cervical ectropion, vulvar intraepithelial neoplasia, dystrophic lesions, melanosis and many other conditions¹. These treatments have also obtained US FDA clearance, and since then thousands of such procedures have been performed in many countries. A high rate of success, with only minor complications, was reported when performing ablation of the lower genital tract, treatment of multifocal and multicentric lesions, excisions and tissue coagulation.

As an interesting and unexpected side-effect, many patients reported that they felt a vaginal tightening effect following these Er:YAG treatments, which resulted also in their enhanced sexual experience. This discovery initiated further research in the direction of developing a minimally invasive, non-surgical and non-ablative erbium treatment for vaginal relaxation syndrome (VRS).

The first studies of the thermal effects of a non-ablative Er:YAG laser on human soft tissue, using precisely controlled, sequentially packaged bursts of erbium long pulses (Fotona 'SMOOTH mode') were performed by Majaron and colleagues in 2000² and Drnovsek and colleagues in 2004³. The studies revealed that deep collagen remodeling and new collagen synthesis occur as a result of the SMOOTH-mode treatment. Collagen exposed to an appropriate temperature increase results in the sudden contraction of its fibers, leading to the contraction and shrinking of the irradiated bulk tissue⁴. The thermal effect on collagen is not just momentary during exposure to increased temperature, but it continues throughout the processes of collagen remodeling and neocollagenesis, resulting in the generation of new collagen and an overall improvement of tightness and elasticity of the treated tissue.

Based on the above findings, SMOOTH-mode Er:YAG lasers also began to be used on mucosal tissue. The first experiences in targeting mucosal tissue were intra-orally. Application of several passes of SMOOTH-mode pulses on the soft palate produces tissue contraction, which is an ideal non-invasive method for treating snoring and apnea complications. The first trials with SMOOTH-mode erbium tightening of the vaginal canal had already begun in 2008/2009⁵. Tightening of the vaginal canal and consequently the improvement of sexual gratification were observed⁵.

Correspondence: Z. Vizintin, Fotona, Stegne 7, 1000 Ljubljana, Slovenia; E-mail: zdenko.vizintin@fotona.com

These trials also revealed another important beneficial effect of the SMOOTH-mode Er:YAG treatment – the improvement of stress urinary incontinence (SUI) in women.

Since then, special G-set applicators (Figure 1) have been designed to enable a uniform and well-controlled irradiation of the whole length and circumference of the vaginal canal. Two protocols for two new minimally invasive, non-surgical and non-ablative procedures were developed and clinically validated: IntimaLase® (for VRS) and IncontiLase® (for SUI)⁵⁻⁷. During the last 4 years, the use of erbium SMOOTH technology for vaginal tightening and incontinence has rapidly spread around the world and many additional studies have been initiated to further assess and prove this technology and treatment approach.

The wide use of erbium SMOOTH technology brought further discoveries – in 2013 Bizjak-Ogrinc and Sencar reported excellent results achieved in the reduction of pelvic organ prolapses⁸, and in the same year Gaspar presented his pioneering work on vaginal atrophy⁹.

In addition to the above new and exciting procedures with the Er:YAG SMOOTH modality, Er:YAG laser technology is also being used today for ablating various lesions on the cervix and vaginal wall, for the removal of genital warts, resurfacing, whitening and tightening of the vulvar region, as well as labioplasty, lichen sclerosus et atrophicus and many other procedures.

MATERIALS AND METHODS

The IntimaLase® and IncontiLase® protocols are based on heating the vaginal wall mucosa up to approximately 65°C and include two treatment sessions with a 4–6-week interval. The time needed to execute the IntimaLase protocol is approximately 8 minutes, and for IncontiLase around 15 minutes (as measured by Guimaraes⁵).

The protocol for treatment of pelvic organ prolapses (ProlapLase®) is based on the same principle of collagen hyperthermia as are the protocols for vaginal tightening and incontinence, although with a difference in the treatment intensity (increased) and the location of the major area treated

(the prolapsed part of the vaginal wall). The ProlapLase protocol requires three to five sessions at 4–6-week intervals. The number of sessions is dependent on the severity (grade) of the prolapse.

The vaginal atrophy protocol (RenovaLase™) is based on a slightly different concept of milder hyperthermia, whereby the mucosa is warmed up to some 45°C, thus causing the stimulation of cell proliferation via heat shock protein activation, an increase of collagen production as well as anti-inflammatory action. The RenovaLase protocol consists of three sessions at intervals of 3 weeks.

RESULTS OF CLINICAL EVALUATIONS

Measurements of an average shrinkage of the vaginal canal after a single IntimaLase treatment, as measured by Rivera on 27 women, showed 17% shrinkage⁵, while Bezmenko measured an average 56% thickening of the vaginal wall 6 months after two IncontiLase treatments on 77 patients¹⁰. Using MRI measurements of the shrinkage of the vaginal canal cross-section, Bezmenko and colleagues¹⁰ also demonstrated significant shrinkage of the vaginal canal treated with erbium SMOOTH technology.

Several subjective and objective assessment tools were used to measure the efficacy of IntimaLase treatment for the improvement of sexual gratification through tightening of the vaginal canal, namely the Pelvic organ prolapse/urinary Incontinence Sexual Questionnaire (PISQ-12) and Female Sexual Function Index (FSFI), 4-point Likert scales and perineometric measurements. For each assessment tool used, significant improvement was reported. Fistonic and colleagues showed an average improvement in PISQ-12 value of 5.5 points (an increase of average value from 33.8 to 39.3) at 6 months after a single treatment¹¹. Guimaraes interviewed male partners with a 4-grade scale and, 4 months after a single treatment, 69% of partners assessed the improvement as excellent, 27% as good and 4% as mild⁵. Using FSFI questionnaires, Garcia found that 96.6% of patients reported improvement after two sessions of IntimaLase⁵. The first results from Rivera showed that better results were achieved if a second session of erbium SMOOTH treatment was additionally performed, and his findings were also confirmed by the results of Garcia⁵.

Various evaluation tools were used to measure the efficacy of erbium therapy for SUI. Several investigators used the International Consultation on Incontinence Questionnaire-Urinary Incontinence (ICIQ-UI) questionnaires and all found significant reductions in the ICIQ-UI score. Fistonic and colleagues reported a reduction of more than 6 points at 6 months after a single treatment¹¹, Lukanovic reported an improvement of 3.7 points after 3 months and a single session¹², while Gambacciani and Levancini reported more than 6 points of improvement after 3 months and three sessions of erbium therapy¹³. Sencar and Bizjak-Ogrinc used ICIQ-UI to define the incontinence severity index (ISI) according to Klovning; after the treatment, the ISI decreased by 2.6 ± 1.0

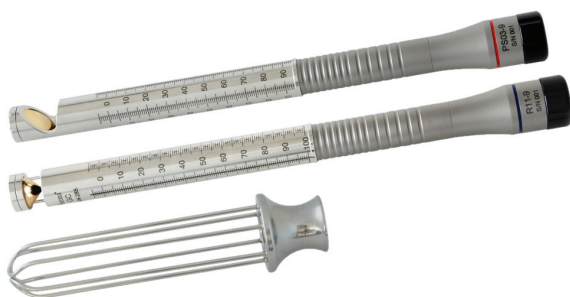

Figure 1 G-Set accessories needed for application of the erbium:YAG laser beam to the vaginal mucosa, consisting of a laser speculum plus angular and circular adapters

points in patients diagnosed with mild UI before the treatment, by 3.6 ± 1.4 points in those with moderate UI, by 5.7 ± 1.8 points in those with severe UI and by 8.4 ± 2.6 points in those with very severe UI. They reported 77% of SUI patients cured (dry) after 12 months¹⁴. Fistonic also measured the reduction of residual urine volume (RUV) and Q-tip angulation. His results showed a large reduction in RUV, which on average decreased from 9 ± 12.1 to 1.6 ± 1.9 ml at 6 months after the treatment. Q-tip angulation under strain reduced from 61.3 ± 24.0 to 47.2 ± 23.7 degrees¹¹. Bezmenko's group performed urodynamic measurements of opening and closing urethral pressures before and 6 months after the erbium therapy and found large increases in both pressures: the opening pressure changed from 13.1 ± 3.7 to 25.1 ± 4.8 mmHg and the closing from 12.2 ± 3.5 to 25.2 ± 4.9 mmHg¹⁰. They also observed some biochemical parameters of connective tissue metabolism and found a significant decrease of the collagen amino acids oxylyzine (from 8.4 ± 0.4 to 5.3 ± 0.5 mkmol/g) and oxyproline (from 5.4 ± 0.3 to 3.7 ± 0.6 μ mol/g)¹⁵. A reduction of both amino acids means a reduced level of collagen degradation and thus more vital and stable collagen. Looking into histological changes after erbium therapy, they found an increase in the quantity and activity of fibroblasts, an increased density of connective tissue and the emergence of neoangiogenesis¹⁶. Gaspar used 3-day voiding diaries for evaluating the efficacy of the IncontiLase procedure and observed a reduction of leakage frequency and quantity at follow-ups at 2, 6, 8 and 12 months. Leakage frequency reduced by 89.8%, 77.5%, 73.5% and 59.2% at 2, 6, 8 and 12 months, respectively¹⁷. The efficacy of the non-ablative Er:YAG laser in the treatment of SUI and the improvement of sexual function in premenopausal, parous women was also evaluated in comparison with a placebo treatment in Lukanovic's randomized, controlled trial, with the laser showing improved SUI and sexual dysfunction significantly better than the placebo¹².

For evaluation of the efficacy of erbium SMOOTH treatment of vaginal atrophy, Gaspar used the following tools: Visual Analog Scale (VAS) (0 = no symptoms, 1 = mild, 2 = moderate and 3 = severe) for assessment of the severity of atrophy symptoms (pain, dryness, irritation and leukorrhea), maturation value and pH value. He also made histological analyses of the vaginal mucosa at 3 months after the treatment⁹ and found significant improvement in all observed parameters: pain reduced from 2.44 ± 0.65 to 1.08 ± 1.00 , dryness from 2.24 ± 0.60 to 1.04 ± 0.89 , irritation from 2.04 ± 0.79 to 0.96 ± 0.93 and leukorrhea from 2.28 ± 0.83 to 0.83 ± 0.79 at the 6-month follow-up. Maturation value improved from 20.8 to 47.9 points at 6 months, while the pH value decreased from 5.0 ± 0.4 to 4.1 ± 0.4 after 3 months, showing a return of vaginal acidity. Histology showed significant changes in the tropism of the vaginal mucosa. Gambacciani and colleagues¹⁸ also observed the atrophy symptoms of pain and dryness and measured the Vaginal Health Index Score (VHIS). After RenovaLase treatment, they reported a reduction of VAS score (on a scale from 0 to 10) for both

dyspareunia and dryness of more than 5 points and an increase of VHIS by 9 points. In studies by Gaspar and Gambacciani, the laser treatment of vaginal atrophy was compared with hormonal replacement therapy (HRT). Gaspar found that the laser treatment, in comparison to HRT, provides significantly greater and longer-lasting improvement in maturation value, pH and the signs and symptoms of vaginal atrophy⁹. Similarly, Gambacciani's results for dryness, dyspareunia and VHIS showed that the Er:YAG treatment is significantly better than HRT¹⁸.

Assessment of the efficacy of laser treatment for pelvic organ prolapses using the erbium ProlapLase protocol was performed by observation of the prolapse degree, measured with the Baden-Walker scale. Bizjak-Ogrinc and Sencar reported on a study performed on 61 patients having prolapses of grade II or higher¹⁹. Before the treatment there were 40 patients with cystocele of grade II, 15 of grade III and 6 of grade IV. At the final follow-up, the great majority of patients (58, or 95%) reduced their prolapse grades by at least one grade, 27 of them (44%) by two grades and 8 (13%) even by three grades. At the 12-month follow-up, 85% of the patients had either grade 0 or I prolapse and the remaining 15% of patients had grade II prolapses.

The treatment discomfort for all of these four protocols was very low (the maximum score was 3 on a 10-point scale) and a large majority of the patients assessed their improvement very positively. There were no adverse effects of these treatments reported.

DISCUSSION

There are many approaches to the treatment of vaginal laxity, urinary incontinence, pelvic organ prolapses and vaginal atrophy, ranging from conservative methods to the most complex surgical interventions. However, none of the existing procedures was ideal and most presented multiple challenges. Such a situation called for a search for new therapeutic methods for all four of the discussed indications.

Erbium SMOOTH technology for minimally invasive treatments in gynecology is based on a concept of a controlled heating of the vaginal mucous tissue. A precisely controlled sequence(s) of sub-ablative Er:YAG laser pulses are delivered to the mucous tissue in order to achieve a controlled heating of the collagen in the deeper mucosa layers without overheating the mucosa surface. Published data show that the shortening of the collagen fibrils without irreversible denaturation of their structure requires that temperatures do not exceed the optimal temperature range of 60–70°C²⁰. Our *in vivo* thermal camera measurements show that the erbium SMOOTH treatments using a Fotona SP Dynamis laser system with an Er:YAG 2940-nm laser and the IntimaLase® and IncontiLase® protocols for vaginal tightening and stress urinary incontinence result in the temperature increase of vaginal wall mucosa up to approximately 65°C, i.e. to the optimal temperature range, without exceeding the

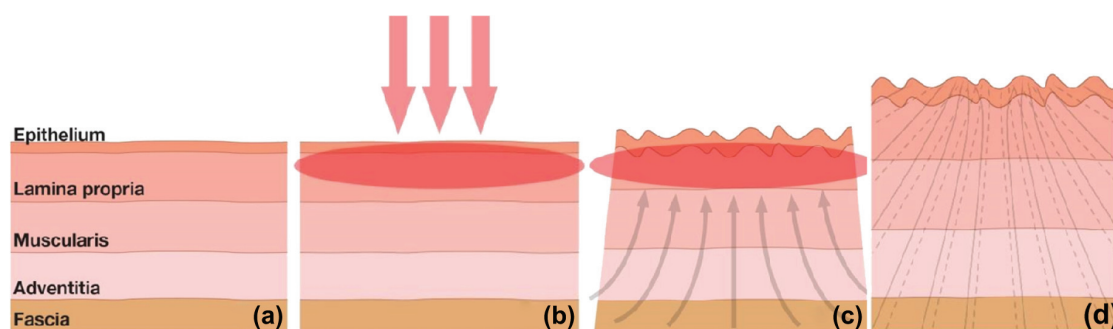


Figure 2 Mechanism of action of non-ablative SMOOTH-mode erbium laser on the vaginal mucosa: (a) the structure of vaginal mucosa consisting of the epithelium, lamina propria, muscularis, adventitia and fascia; (b) irradiation by special SMOOTH-mode pulsing sequence of erbium:YAG laser produces collagen hyperthermia in the epithelium and lamina propria; (c) temperature increase to around 65°C on the mucosa surface causes immediate shrinkage of the upper layers of the vaginal wall as well as mechanical pull of the lower lying structures; (d) 6 months after the treatment there is a significant thickening of the vaginal wall due to new collagen synthesis

temperature threshold for surface ablation or irreversible denaturation of collagen.

The Er:YAG laser irradiation acts almost like a surface heater due to the extremely shallow penetration depth of its optical mid-infrared radiation, and relies on heat diffusion to affect deeper layers of the mucosa. Collagen exposed to an appropriate temperature increase results in a contraction of its fibers, leading to the contraction and shrinkage of the irradiated bulk mucous tissue. The thermal effect on collagen is not just momentary during exposure to increased temperature, but continues throughout the processes of collagen remodeling and neocollagenesis, resulting in the generation of new collagen and an overall improvement of the tightness and elasticity of the treated tissue. After immediate tissue shrinkage, the process of neocollagenesis could take up to 6 months to complete (Figure 2).

CONCLUSION

We believe that the non-ablative erbium:YAG laser is an efficacious and safe new method for the treatment of vaginal laxity, stress urinary incontinence, pelvic organ prolapses and vaginal atrophy and that it will soon become the treatment of choice for all of these indications.

Conflict of interest Z. Vizintin, M. Lukac and M. Kazic are employees of Fotona; M. Tettamanti is a business partner of Fotona.

Source of funding No special funding of this paper.

References

- Mansilla EC, Pidal CM, Rios VE, San Martino JA. Erbium YAG Láser. Nuevo Aporte Terapeutico en Tracto Genital Inferior. Presented at the 11th International Congress of Cervical Pathology and Colposcopy, Barcelona, Spain, June 9–13 2002.
- Majaron B, Srinivas SM, Huang HL, Nelson JS. Deep coagulation of dermal collagen with repetitive Er:YAG laser irradiation. *Lasers Surg Med* 2000;26:215–22
- Drnovsek B, Beltram M, Pizem J. Repetitive Er:YAG laser irradiation of human skin: a histological investigation. *Lasers Surg Med* 2004;35:146–51
- Goldberg DJ. *Ablative and Non-ablative Facial Skin Rejuvenation*. London, New York: Martin Dunitz, 2003:1–8
- Vizintin Z, Rivera M, Fistončić I, et al. Novel minimally invasive VSP Er:YAG laser treatments in gynecology. *J LA & HA* 2012;1:46–58
- Fistončić I, Findri-Gustek S, Fistončić N. Minimally invasive laser procedure for early stages of stress urinary incontinence (SUI). *J LA & HA* 2012;1:67–74
- Gaviria JE, Lanz LA. Laser vaginal tightening (LVT) – evaluation of a novel noninvasive laser treatment for vaginal relaxation syndrome. *J LA & HA* 2012;1:37–45
- Bizjak Ogrinc U, Sencar S. Non-surgical minimally invasive Er:YAG laser treatment for higher-grade cystocele. Presented at NDP 373, 38th Annual Meeting of International Urogynecological Association, Dublin, May 28–June 1, 2013
- Gaspar A. Comparison of new minimally invasive Er:YAG laser treatment and hormonal replacement therapy in the treatment of vaginal atrophy. *Climacteric* 2014;17(Suppl 1):48–108, P 124 (Abstr)
- Bezmenko AA, Schmidt AA, Koval AA, Karpishchenko ZM. Clinical and morphological study of efficacy of IncontiLase and IntimaLase in treatment of female stress urinary incontinence. Study report, Military Medical Academy Kirov, St. Petersburg, Russia, February 2014
- Fistončić N, Fistončić I, Findri-Gustek S, Bilajac Turina I, Kristofic I, Franic D. Laser treatment for stress urinary incontinence (SUI) in women. Presented at the 44th International Continence Society Congress, Rio de Janeiro, Brazil, 20–24 October 2014
- Lukanovic A, et al. Non-ablative Er:YAG laser therapy effect on SUI related quality of life and sexual function: a randomized controlled trial. Presented at the 44th International Continence Society Congress, Rio de Janeiro, Brazil, 20–24 October 2014

13. Gambacciani M, Levancini M. Short-term effect of vaginal erbium laser on the genitourinary syndrome of menopause. *Minerva Ginecol* 2015;67:1–2
14. Bizjak-Ogrinc U, Sencar S, Vizintin Z. Minimally invasive non-surgical ErYAG laser treatment for female stress and mixed urinary incontinence – one year follow-up. Proceedings of *20th World Congress on Controversies in Obstetrics, Gynecology & Infertility*, Paris, France, 4–7 December 2014
15. Bezmenko AA, Elkin GI, Schmidt AA, et al. Treatment of stress urinary incontinence in women with Er:YAG laser: some biochemical parameters of connective tissue metabolism. [Russian] *J Exp Clin Urol* November 2014
16. Bezmenko AA, Schmidt AA, Koval AA, Sibirev SA, Karpishchenko ZhM, Gayvoronskikh DI. Morphological substantiation of applying the Er:YAG laser for the treatment of stress urinary incontinence in women. *J Obstet Women Dis* 2014;No.3. <http://ecuro.ru/en/journal/number-3-2014>
17. Gaspar A, Vizintin Z. Assessment of efficacy of Er:YAG laser treatment for female SUI using 3 days voiding diary – pilot study with 12 months follow-up. Presented at *the 2nd Annual Meeting of the Mediterranean Incontinence and Pelvic Floor Society*, Nimes, France, 26–29 November 2014. http://www.jowd.ru/arhiv/JOWD_3_2014/JOWD_3_2014.html
18. Gambacciani M, Levancini M, Cervigni M. Vaginal erbium laser as second-generation thermotherapy for the genitourinary syndrome of menopause. *Climacteric* 2015;18:757–63
19. Sencar S, Bizjak-Ogrinc U, Vizintin Z. Evaluation of Er:YAG laser treatment for higher grade pelvic organ prolapses – 1 year follow-up. Presented at the *20th World Congress on Controversies in Obstetrics, Gynecology & Infertility*, Paris, France, 4–7 December 2014
20. Hayashi K, Thabit G, Massa KL, et al. The effect of thermal heating on the length and histologic properties of the glenohumeral joint capsule. *Am J Sports Med* 1997;25:108–12